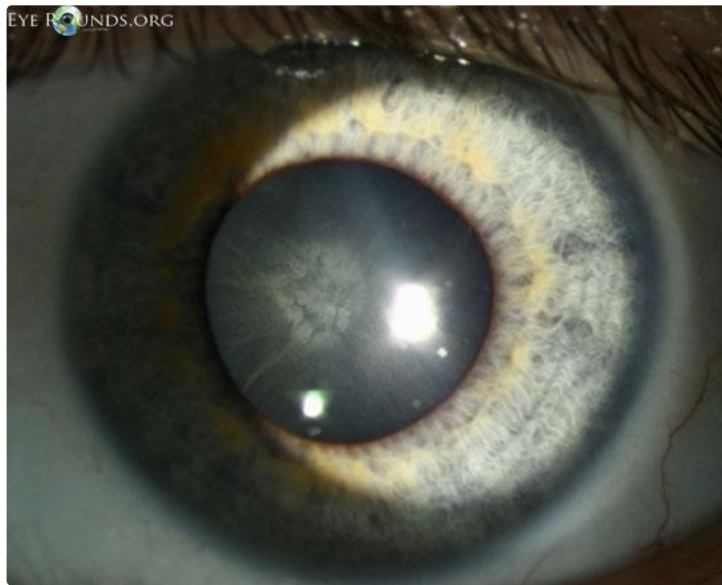

Ocular Syphilis Presenting with Posterior Subcapsular Cataract

Category(ies): Cataract, Systemic Disorders

Contributor: Matt Weed, MD

see case: Weed M, Johns AT, Thurtell M. [Ocular Syphilis Presenting with Posterior Subcapsular Cataract and Optic Disc Edema: 30-year-old female with progressive bilateral vision loss](http://www.EyeRounds.org/cases/157-ocular-syphilis.htm) EyeRounds.org. Posted Oct 10, 2012. Available from <http://www.EyeRounds.org/cases/157-ocular-syphilis.htm>.



[Enlarge](#) [Download](#)

Severe optic disc edema in the setting of syphilis with AIDS (Acquired Immunodeficiency Syndrome)

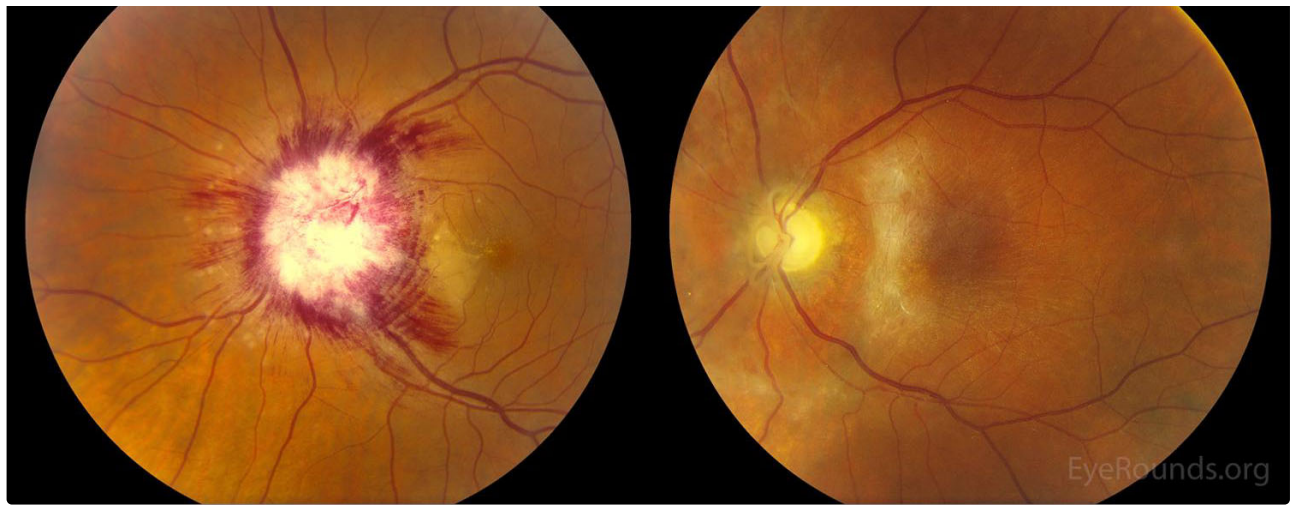
Contributor: [Elaine Binkley, MD](#), [Tyler Risma, MD](#), [James Folk, MD](#)

Photographer: CC

A 50-year-old male presented with 10 days of progressive vision loss in the left eye (OS) as well as fevers, fatigue, and unintentional weight loss. Visual acuity was hand motion OS. Slitlamp examination showed 1+ anterior vitreous cells. On funduscopy, he had severe optic disc edema with 360 degrees of peripapillary cotton wool spots and nerve fiber layer hemorrhages, along with a serous retinal detachment with peripapillary yellowish inflammation in the outer retina around the disc (A). He was found to have active syphilis with AIDS (Acquired Immunodeficiency Syndrome). He was treated with penicillin at that time and anti-retroviral therapy was ultimately initiated by the infectious diseases service. At 10 months follow up, his vision was light perception. He had severe optic atrophy, retinal thinning around the optic nerve, and an epiretinal membrane (B).

Patients with ocular syphilis may present with findings most pronounced in the area near the optic disc. The macular chorioretinal lesion just temporal to the optic disc is consistent with the typical placoid lesions seen with syphilitic uveitis.





On funduscopy, he had severe optic disc edema with 360 degrees of peripapillary cotton wool spots and nerve fiber layer hemorrhages, along with a serous retinal detachment with peripapillary yellowish inflammation in the outer retina around the disc (A). He was found to have active syphilis with AIDS (Acquired Immunodeficiency Syndrome). He was treated with penicillin at that time and anti-retroviral therapy was ultimately initiated by the infectious diseases service. At 10 months follow up, his vision was light perception. He had severe optic atrophy, retinal thinning around the optic nerve, and an epiretinal membrane (B).

[Enlarge](#) [Download](#)

Reference:

- Agarwal A. 2012. Gass' Atlas of Macular Diseases. Chapter 10: Luetic chorioretinitis. Fifth edition. 818-829.

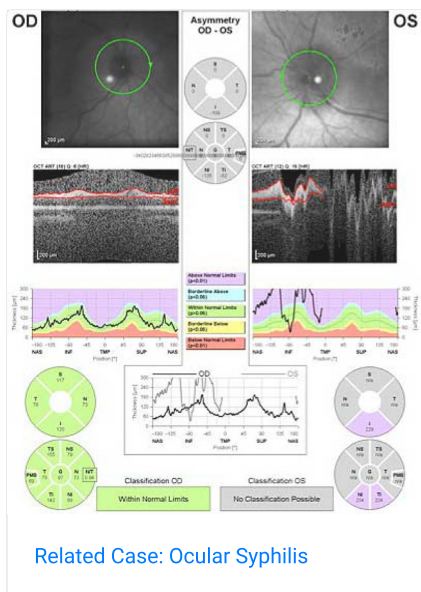
Image Permissions:



Ophthalmic Atlas Images by [EyeRounds.org](#), [The University of Iowa](#) are licensed under a [Creative Commons Attribution-NonCommercial-NoDerivs 3.0 Unported License](#).



Related Articles



Address

University of Iowa
Roy J. and Lucille A. Carver College
of Medicine
Department of Ophthalmology and
Visual Sciences
200 Hawkins Drive
Iowa City, IA 52242

[Support Us](#)

Legal

Copyright © 2019 The University of
Iowa. All Rights Reserved
[Report an issue with this page](#)
[Web Privacy Policy](#) |
[Nondiscrimination Statement](#)

Related Links

[Cataract Surgery for Greenhorns](#)
[EyeTransillumination](#)
[Gonioscopy.org](#)
[Iowa Glaucoma Curriculum](#)
[Iowa Wet Lab](#)
[Patient Information](#)
[Stone Rounds](#)
[The Best Hits Bookshelf](#)

EyeRounds Social Media

Follow



[Receive notification of new cases,
sign up here](#)
[Contact Us](#)
[Submit a Suggestion](#)